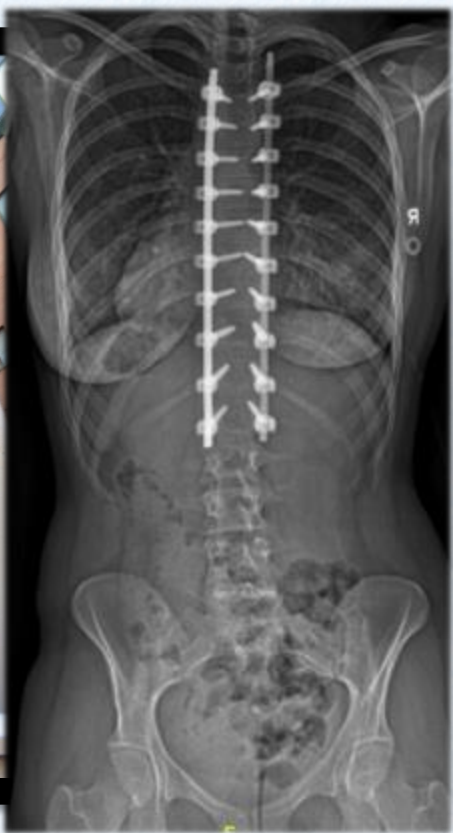
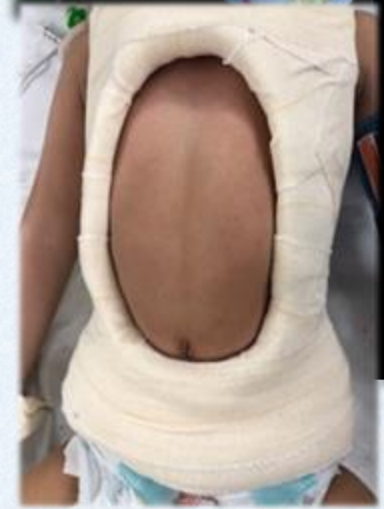
Empowering Resilience:

Addressing Misconceptions, Early Diagnosis and Non-Surgical Strategies for Scoliosis

Jennifer Dermott, PT, MSc, PhD candidate





Avery

11 years old

Healthy

Pre-pubescent

Dance, basketball



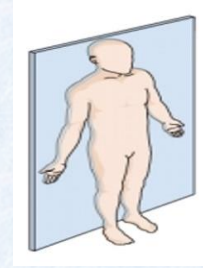
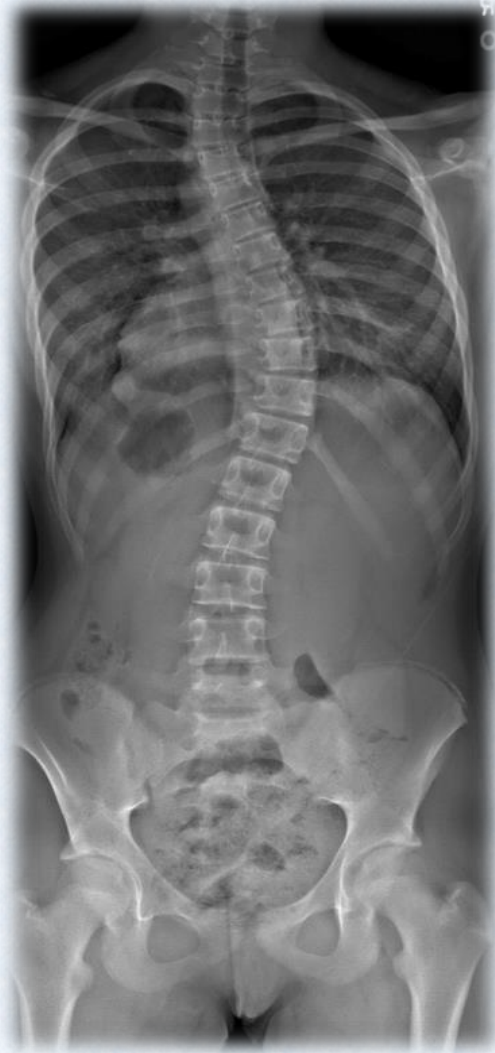Scoliosis



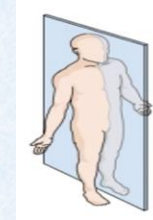Lateral curvature of the spine greater than 10 degrees

(Taber's Medical Dictionary)

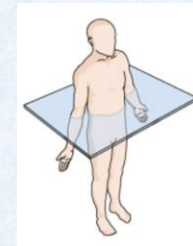
3-dimensional deformity of the spine with varying degrees of **coronal**, **sagittal**, and **axial** involvement



Coronal Plane
-lateral curvature



Sagittal Plane
-kyphosis/lordosis



Axial Plane
-rotation

Prevalence

- **2-4%**

Etiology

- **Idiopathic**
- Congenital, Syndromic, Neuromuscular

Age of onset

- 0-2 years, 3-9 years
- **10+ years**

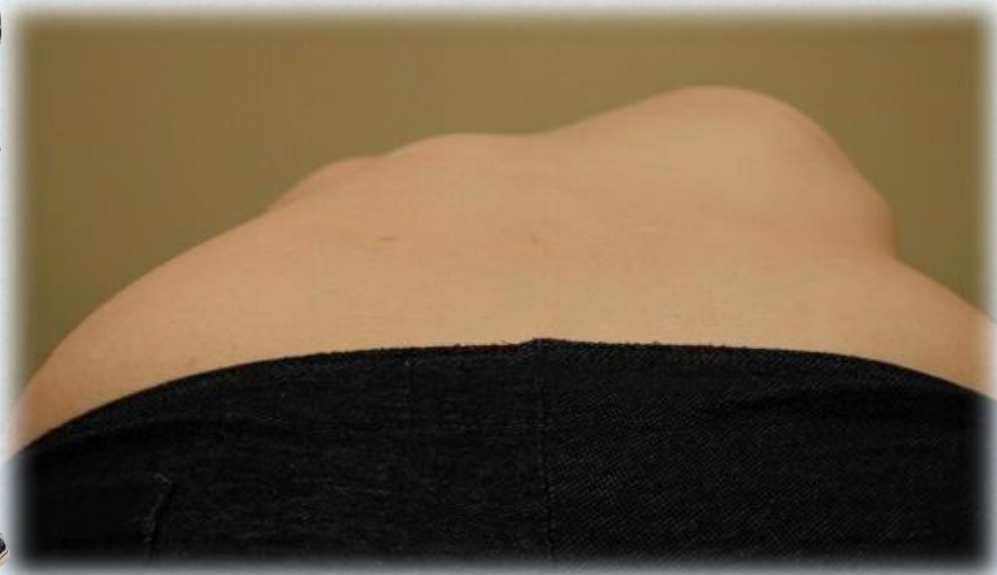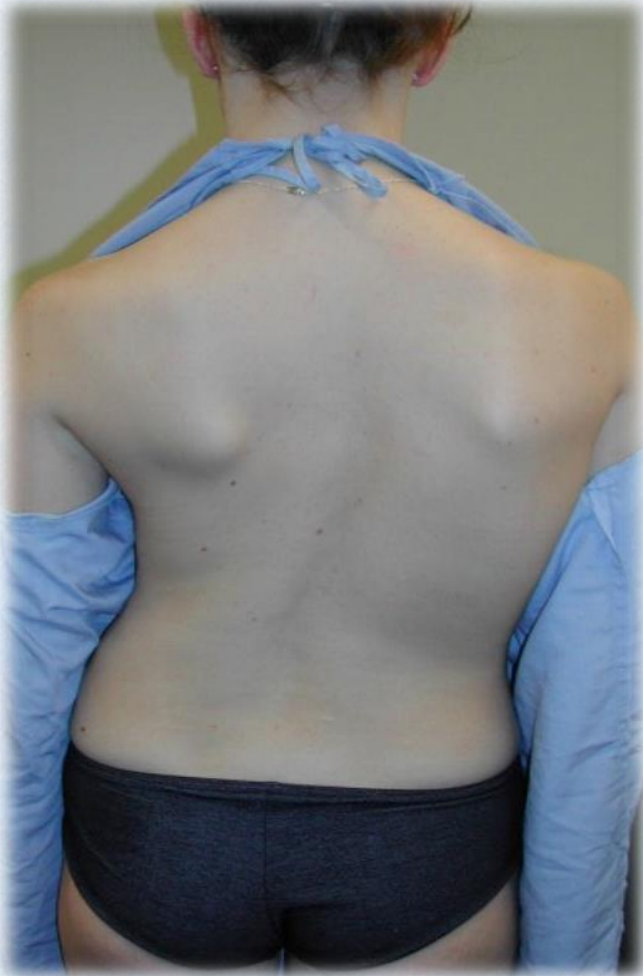Propensity

- **Female**
- 1:1 small curves, 7:1 large curves

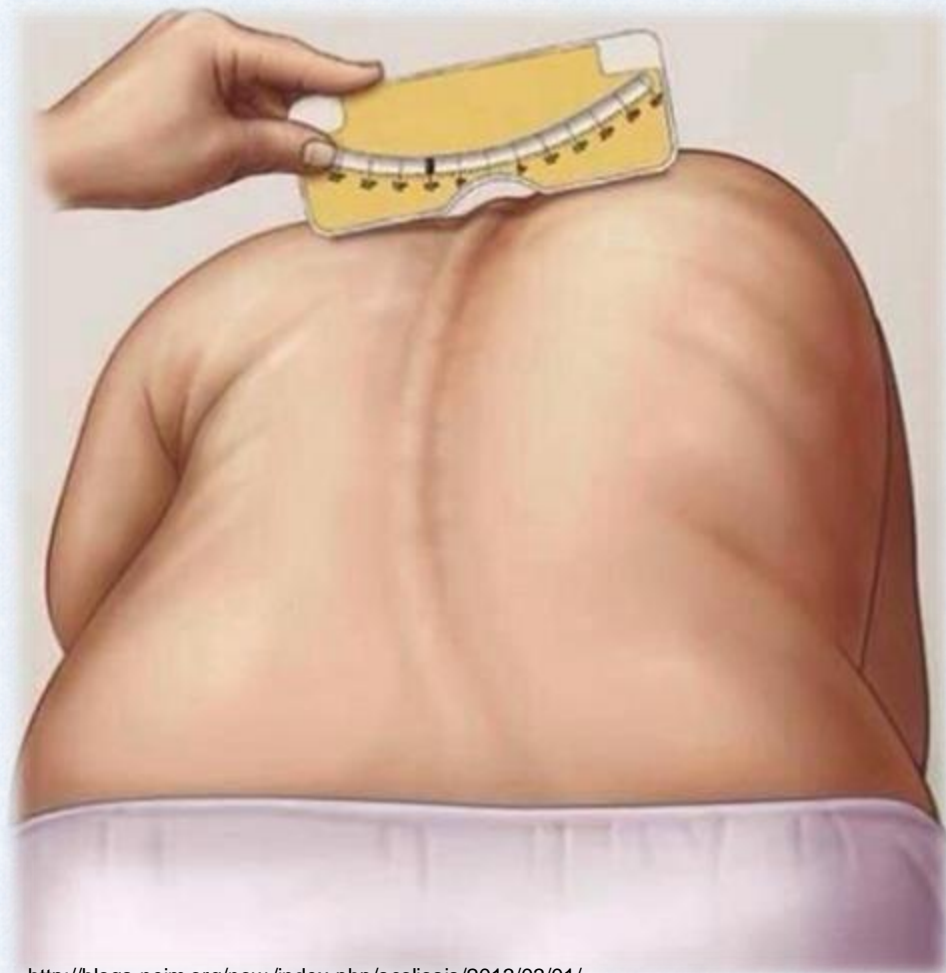
Profile

- **Right main thoracic**

Clinical Presentation

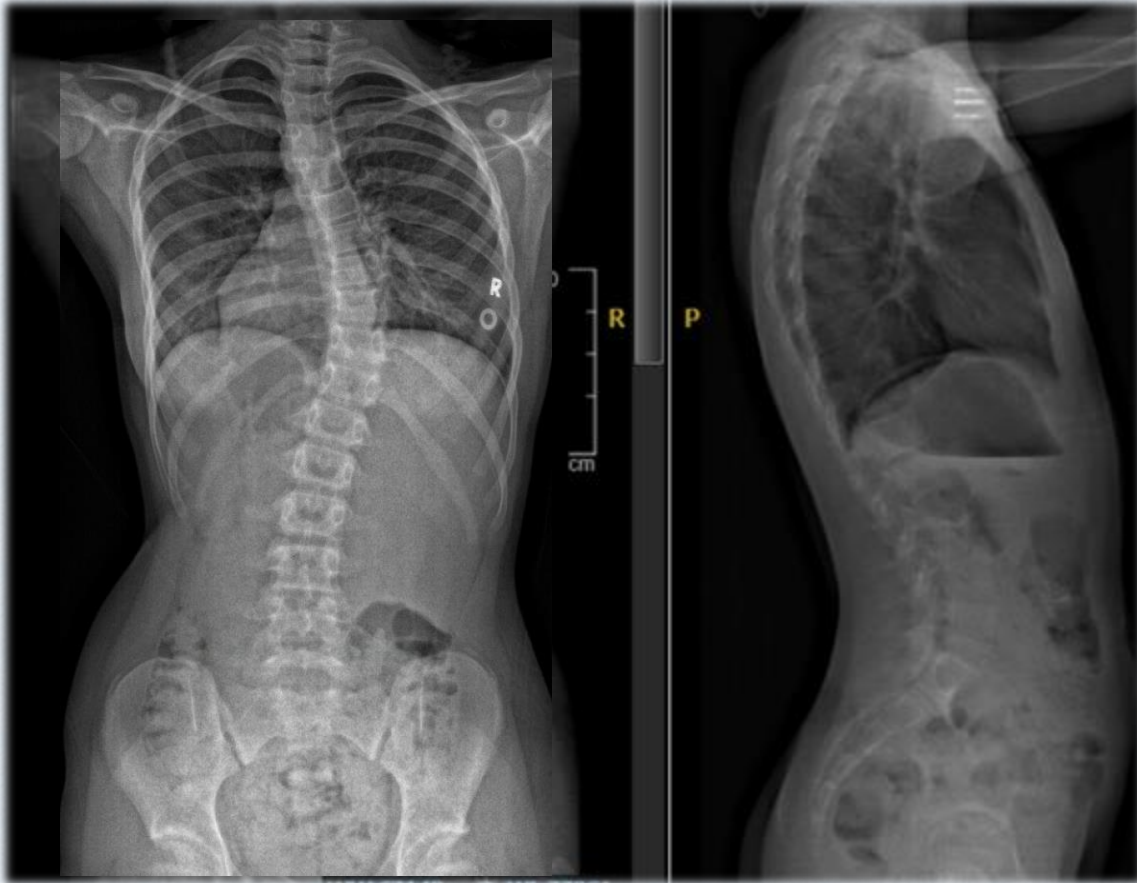


Adam's forward bend test



<http://blogs.nejm.org/now/index.php/scoliosis/2013/03/01/>





Radiographic Presentation

Side= corresponds to convexity
levo- versus dextro-

Location= level of apex

Thoracic (T2-T11/12 disc)

Thoracolumbar (T12-L1)

Lumbar (L1/2 disc-L4)

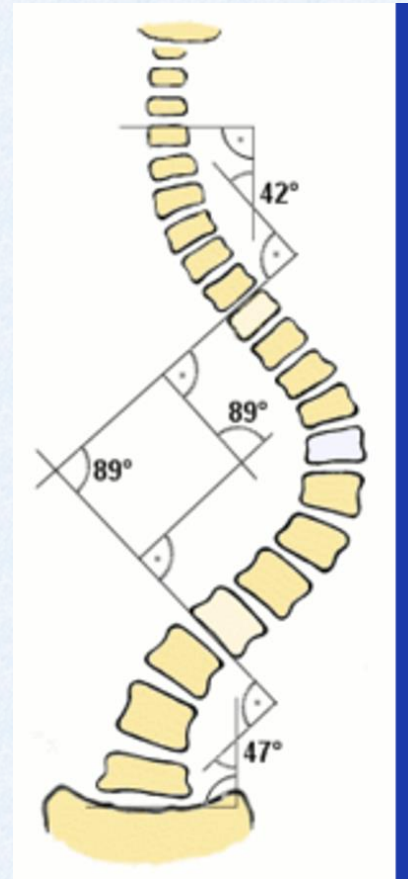
SRS definition

Magnitude= Cobb angle

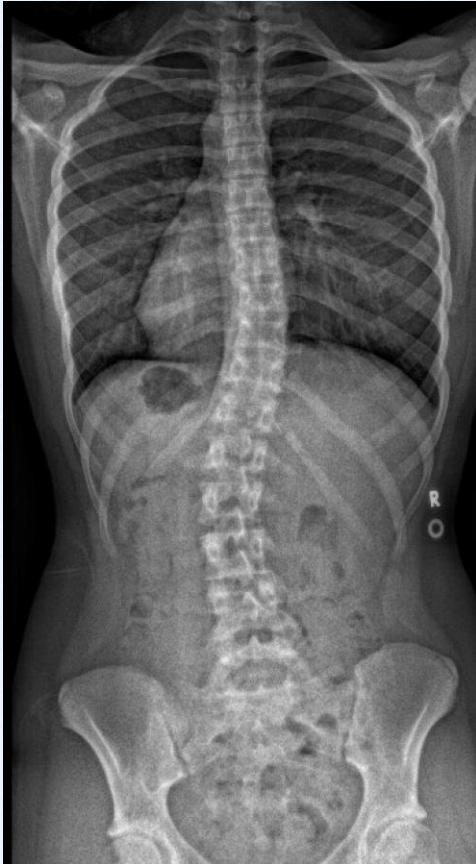Small- 10-30 degrees

Medium- 30-50 degrees

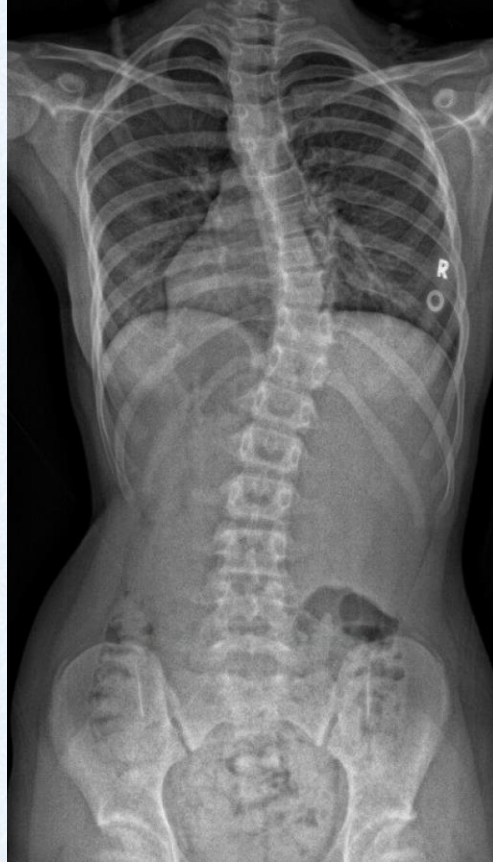Large- >50 degrees



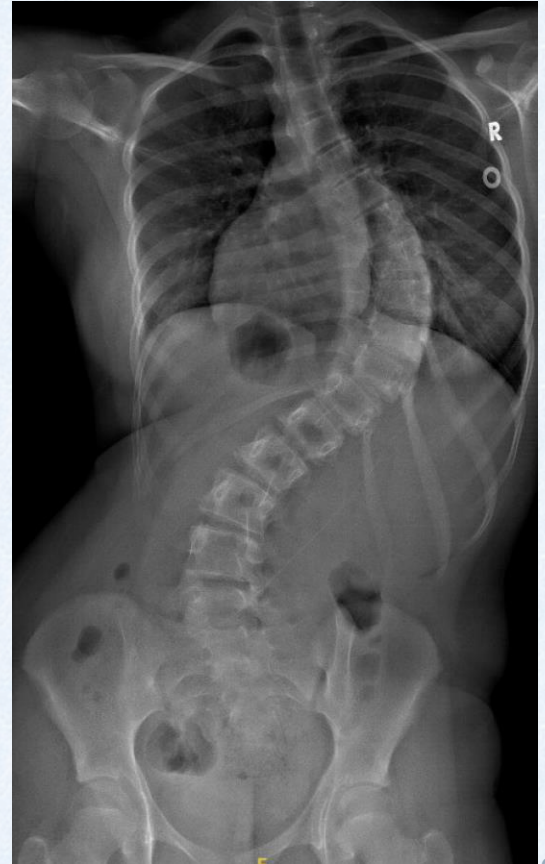
Small Curve



Medium Curve

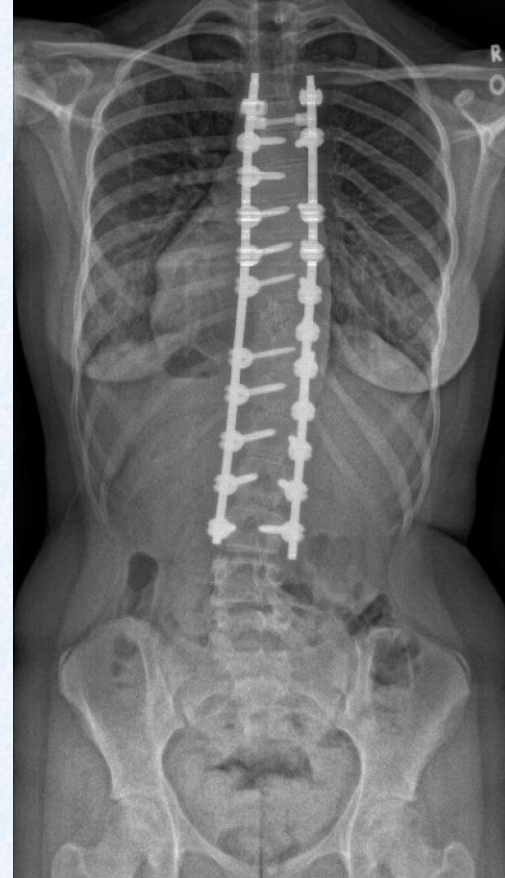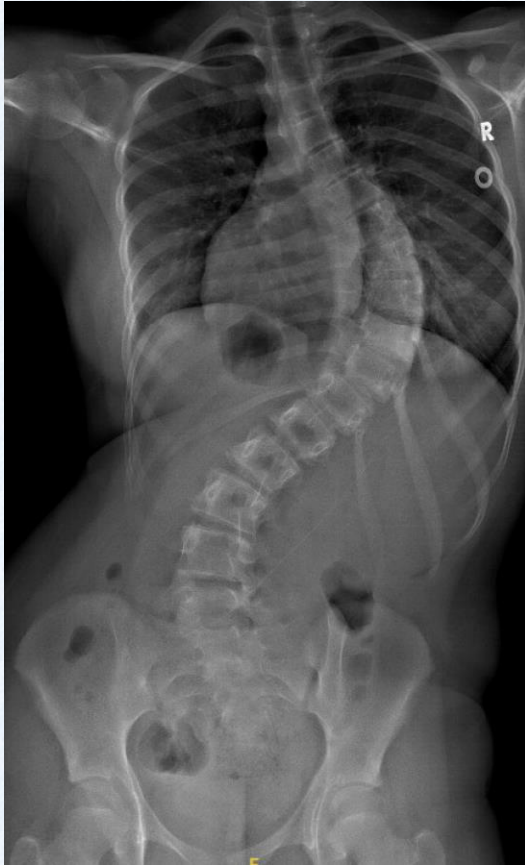


Large Curve



Surgical Treatment

Surgery is for severe curves...



Why only severe curves?

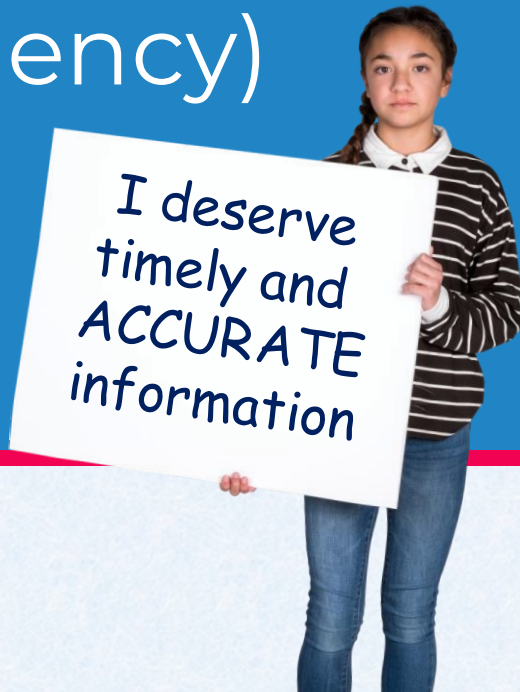
The ramifications of mild and moderate scoliosis are minimal



Why?

Because the human body is **RESILIENT!**

Common Misconceptions (that undermine resiliency)

A young girl with dark hair in a braid, wearing a black and white striped sweater and blue jeans, stands on the right side of the slide. She is holding a white rectangular sign with black text. The sign reads: "I deserve timely and ACCURATE information". The word "ACCURATE" is in all caps. The background is a solid blue color with a horizontal orange and red stripe near the bottom.

I deserve
timely and
ACCURATE
information



Posture



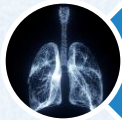Muscle imbalance



Unilateral activity



Any activity



Cardiovascular



PAIN

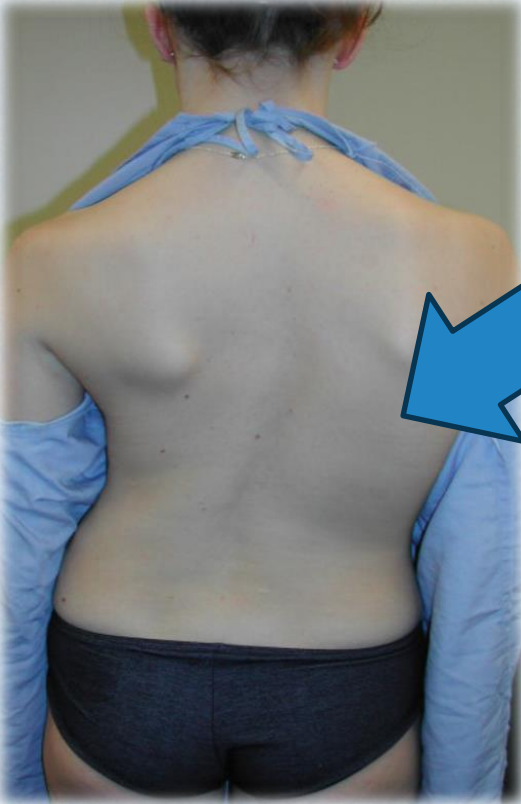


Posture





Muscle imbalance



Medical News

February 26, 1982

Electrical stimulation of muscles replaces braces for scoliosis

Downloaded from: jamanetwork.com

Effectiveness of treatment with a brace in girls who have adolescent idiopathic scoliosis. A prospective, controlled study based on data from the Brace Study of the Scoliosis Research Society.

Nachemson, A L; Peterson, L E

[Author Information](#) ⓘ

Department of Orthopaedics, Göteborg University, Sweden.

The Journal of Bone & Joint Surgery 77(6):p 815-822, Jun 1995.



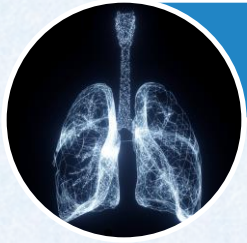Unilateral activity





Any activity

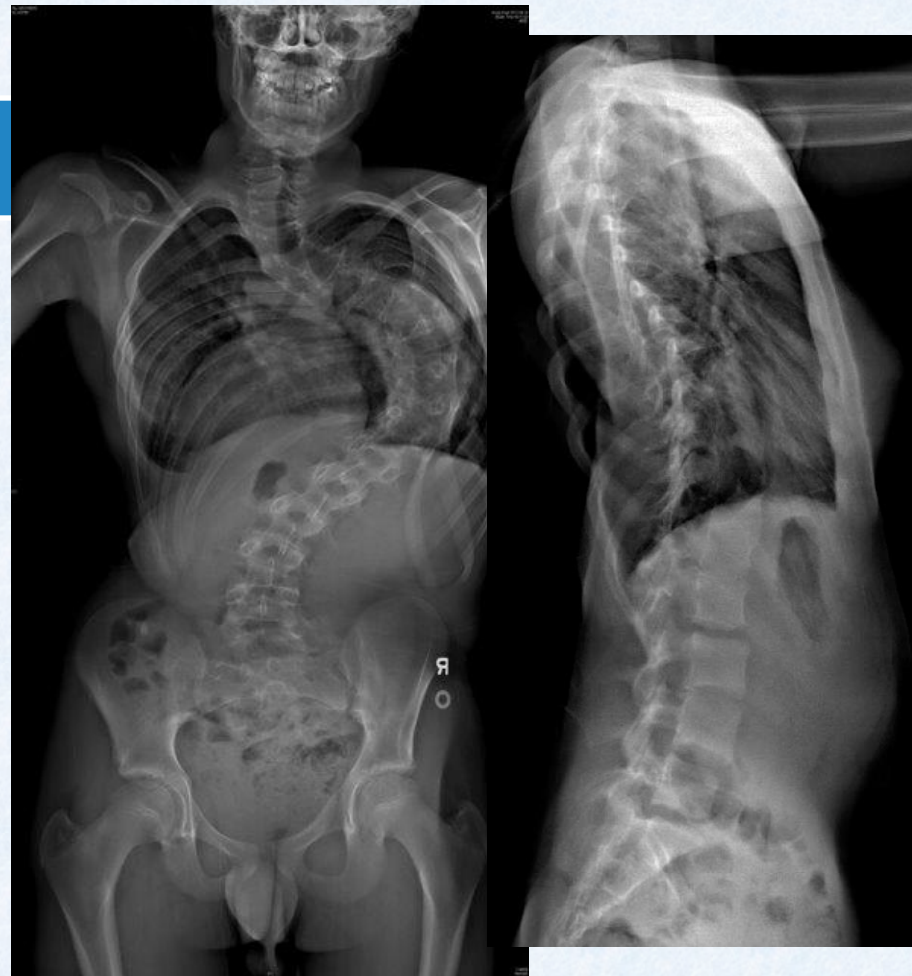



Cardiovascular

Mild to moderate scoliosis should not have negative impact on lung and/or cardiac function.

VERY severe curvatures 90+ or lordotic saggital profiles may





PAIN

➔ **Up to 45%**

Of the general adolescent population

Calvo-Muñoz I, Gómez-Conesa A, Sánchez-Meca J. Prevalence of low back pain in children and adolescents: a meta-analysis. *BMC Pediatr.* 2013 Jan 26;13:14. doi: 10.1186/1471-2431-13-14. PMID: 23351394; PMCID: PMC3571904.

➔ **61% adults**

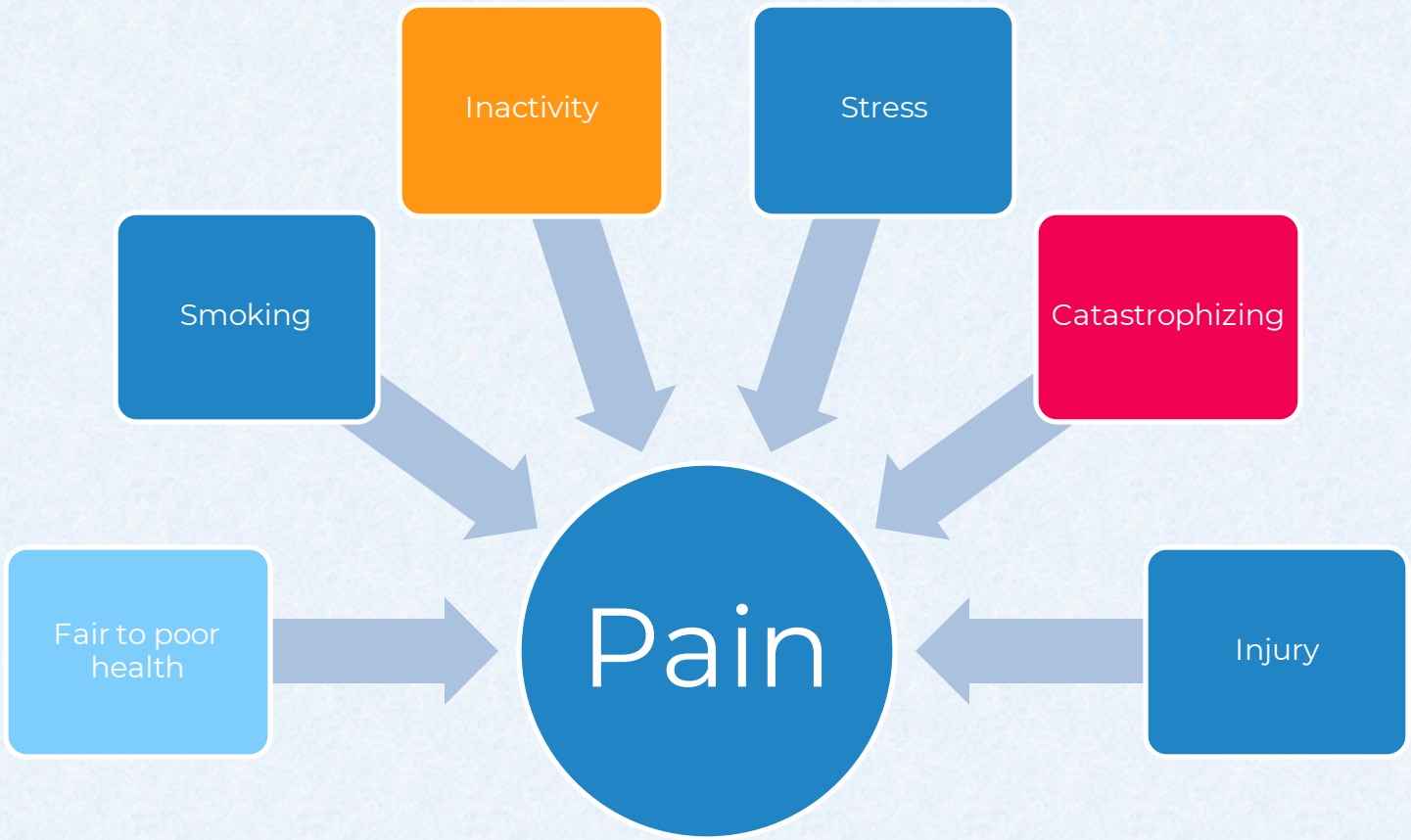
with scoliosis at 51-year follow-up

➔ **68%**

Very little or moderate



Weinstein SL, Dolan LA, Spratt KF, Peterson KK, Spoonamore MJ, Ponseti IV. Health and Function of Patients With Untreated Idiopathic Scoliosis: A 50-Year Natural History Study. *JAMA.* 2003;289(5):559-567. doi:10.1001/jama.289.5.559



Natural history outcomes

J Child Orthop (2013) 7:37–41
DOI 10.1007/s11832-012-0462-7

CURRENT CONCEPT REVIEW

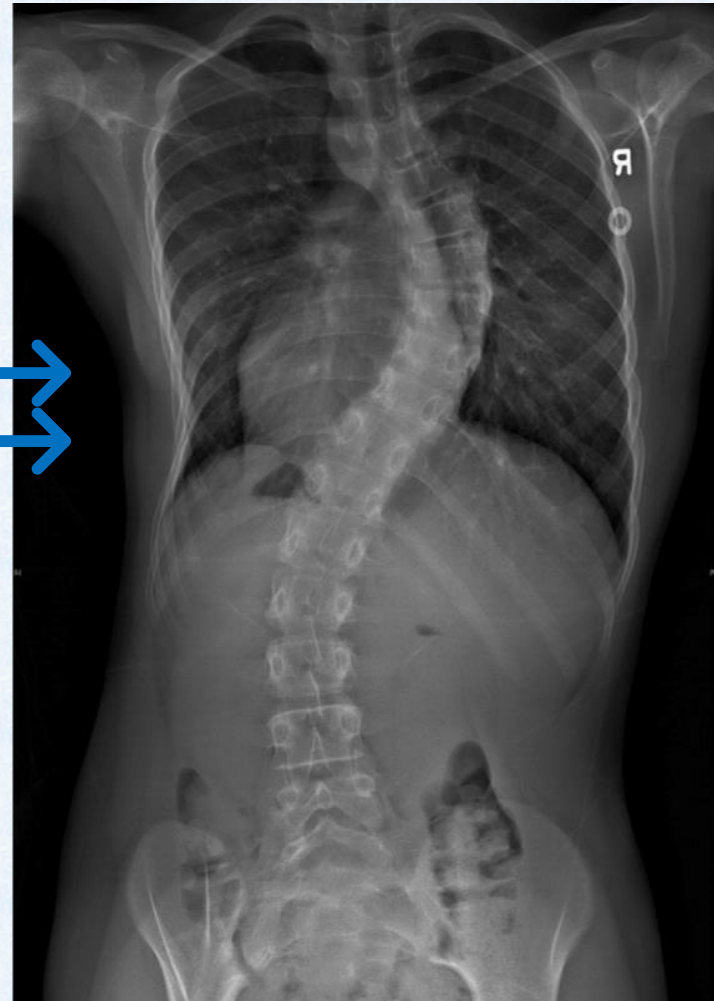
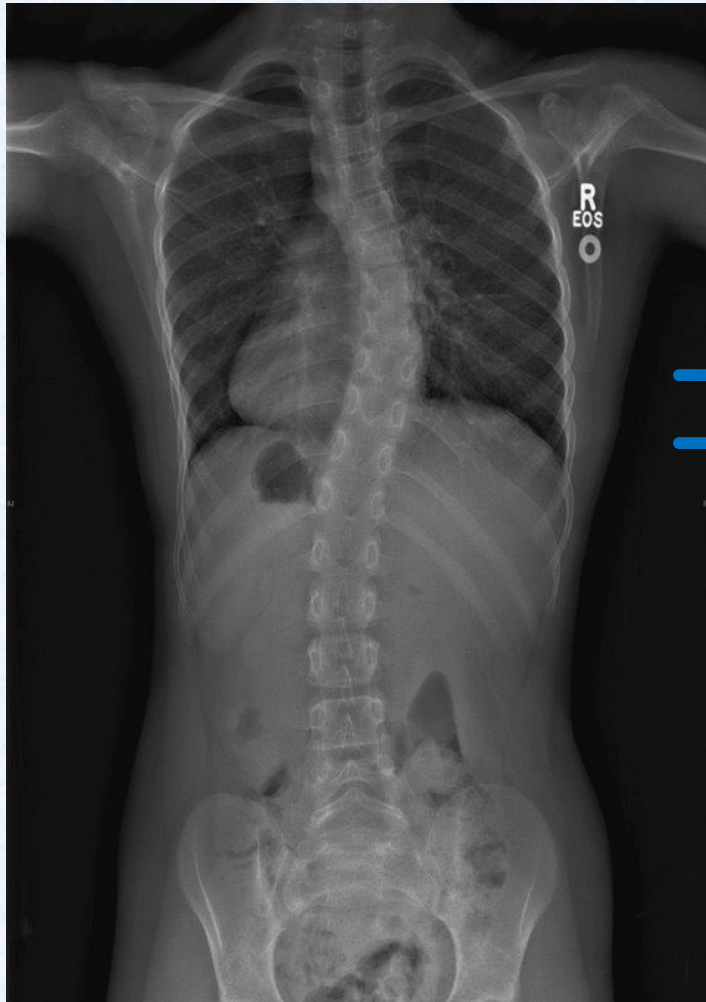
Natural history of adolescent idiopathic scoliosis: a tool for guidance in decision of surgery of curves above 50°

Aina J. Danielsson

Outcome variable	Increased risk or prevalence?	If?
Mortality	No increased risk	
Health impairment	Risk for respiratory failure after 20 years IF	Curve size >110° AND VC % predicted <45 %
Shortness of breath	Increased risk IF	Curve size >80° OR large degrees of rotation
Curve progression	Risk for progression for	Single thoracic curve 50–75° <1°/year
Back pain	Increased prevalence, but mostly mild/occasional	Lumbar curves not worse
Quality of life and function	As the normal population	
Cosmetic problems	Not a problem in most patients	

Brace treatment

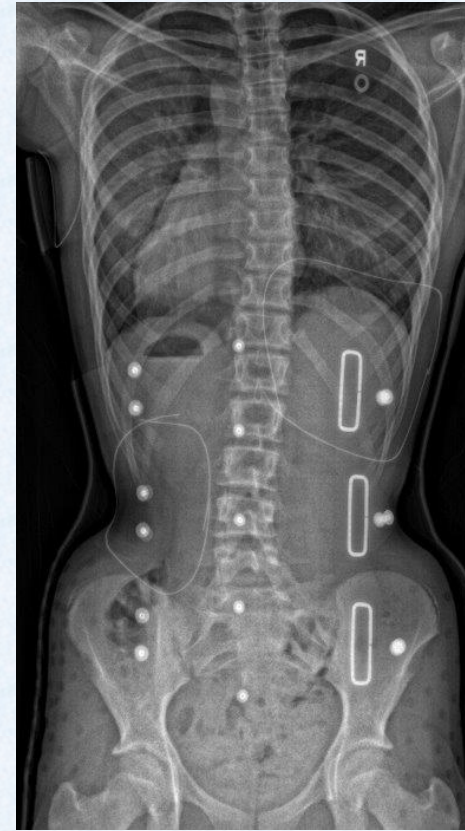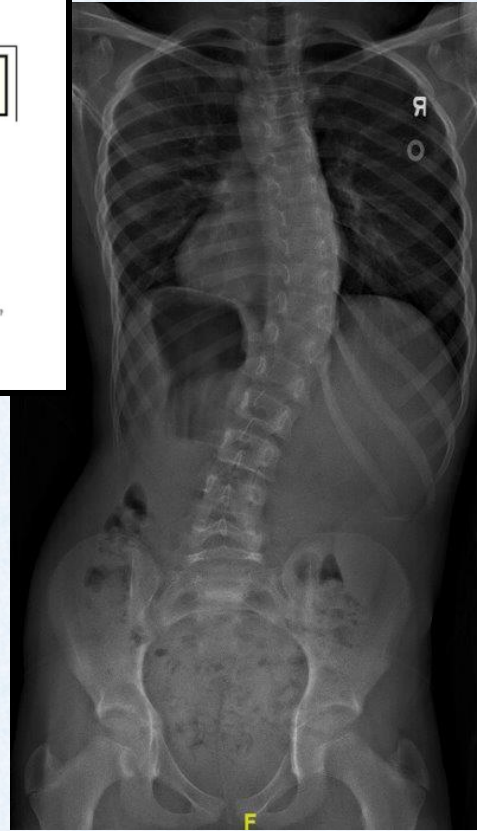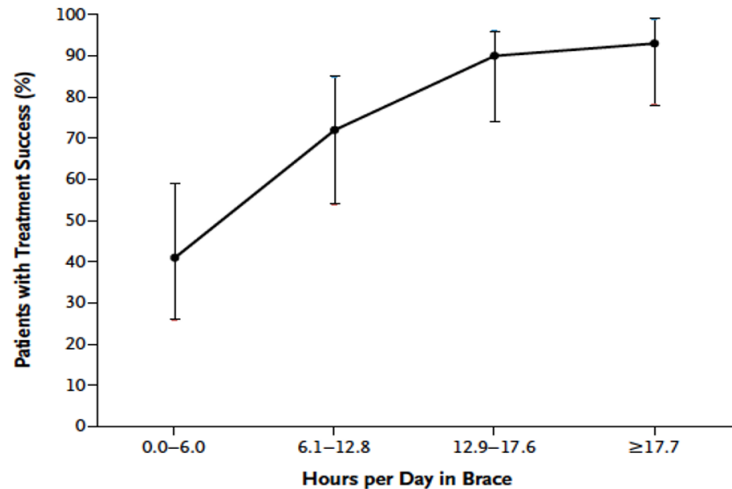
Natural History



ORIGINAL ARTICLE

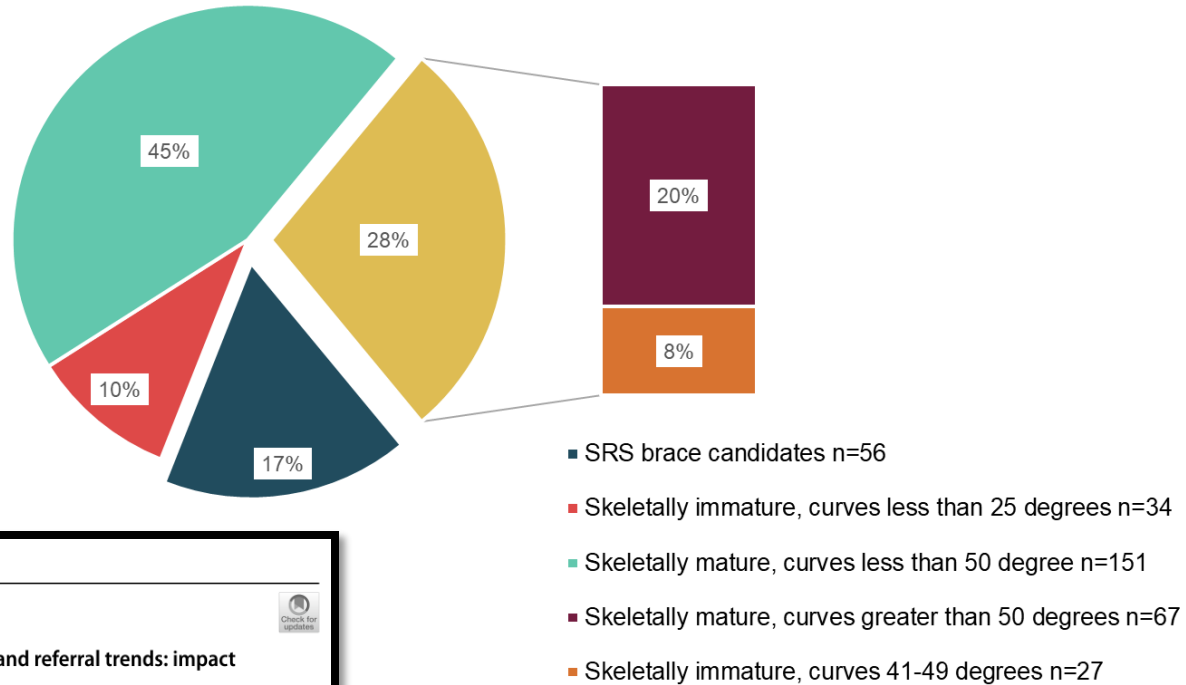
Effects of Bracing in Adolescents with Idiopathic Scoliosis

Stuart L. Weinstein, M.D., Lori A. Dolan, Ph.D., James G. Wright, M.D., M.P.H., and Matthew B. Dobbs, M.D.



Early diagnosis

Fig. 3 Distribution of adolescent idiopathic scoliosis patients presenting to spine clinic for initial assessment





No Child Elects to Wait

Delayed scoliosis surgery for children
in Canada costs the healthcare
system \$44.6 million

No Child Elects to Wait

Timely Access to Pediatric Spinal Surgery

Avery

- Champion scoliosis awareness
- Brace
- Stay active
- Education



References

1. Calvo-Muñoz I, Gómez-Conesa A, Sánchez-Meca J. Prevalence of low back pain in children and adolescents: a meta-analysis. *BMC Pediatr.* 2013 Jan 26;13:14. doi: 10.1186/1471-2431-13-14. PMID: 23351394; PMCID: PMC3571904.
2. Danielsson AJ. Natural history of adolescent idiopathic scoliosis: A tool for guidance in decision of surgery of curves above 50°. *Journal of Children's Orthopaedics.* 2013;7(1):37-41. doi:10.1007/s11832-012-0462-7.
3. de Assis, S.J.C., Sanchis, G.J.B., de Souza, C.G. *et al.* Influence of physical activity and postural habits in schoolchildren with scoliosis. *Arch Public Health* 79, 63 (2021). <https://doi.org/10.1186/s13690-021-00584-6>
4. Farshad M, Götschi T, Bauer DE, Böni T, Laux CJ, Kabelitz M. Long-term outcome of patients with adolescent idiopathic scoliosis seeking nonoperative treatment after a mean follow-up of 42 years. *Spine Deform.* 2022 Nov;10(6):1331-1338. doi: 10.1007/s43390-022-00541-5. Epub 2022 Jul 11. PMID: 35819723; PMCID: PMC9579110.
5. Nachemson AL, Peterson LE. Effectiveness of treatment with a brace in girls who have adolescent idiopathic scoliosis. A prospective, controlled study based on data from the Brace Study of the Scoliosis Research Society. *J Bone Joint Surg Am.* 1995 Jun;77(6):815-22. doi: 10.2106/00004623-199506000-00001. PMID: 7782353.
6. de Assis, S.J.C., Sanchis, G.J.B., de Souza, C.G. *et al.* Influence of physical activity and postural habits in schoolchildren with scoliosis. *Arch Public Health* 79, 63 (2021). <https://doi.org/10.1186/s13690-021-00584-6>
7. Watanabe, Kei MD, PhD*; Ohashi, Masayuki MD, PhD*; Hirano, Toru MD, PhD*; Katsumi, Keiichi MD, PhD†; Mizouchi, Tatsuki MD*; Tashi, Hideki MD*; Minato, Keitaro MD*; Hasegawa, Kazuhiro MD, PhD‡; Endo, Naoto MD, PhD*. Health-Related Quality of Life in Nonoperated Patients With Adolescent Idiopathic Scoliosis in the Middle Years: A Mean 25-Year Follow-up Study. *SPINE* 45(2);p E83-E89, January 15, 2020. | DOI: 10.1097/BRS.00000000000003216
8. Venes, Donald, editor. "Taber's Cyclopedic Medical Dictionary." *Taber's Medical Dictionary*, 24th ed., F.A. Davis Company, 2021.
9. Weinstein SL, Dolan LA, Spratt KF *et al* (2003) Health and function of patients with untreated idiopathic scoliosis: a 50-year natural history study. *JAMA* 289:559–567.

National Day
**for Truth and
Reconciliation**





Thank you

Presentation template by [SlidesCarnival](#)

